

## Acne Treatment by a Dissolvable Micro-Needle Patch

Sung-Yun Kwon

TheraJect Inc., 39270 Paseo Padre #112, Fremont, CA 94538, USA

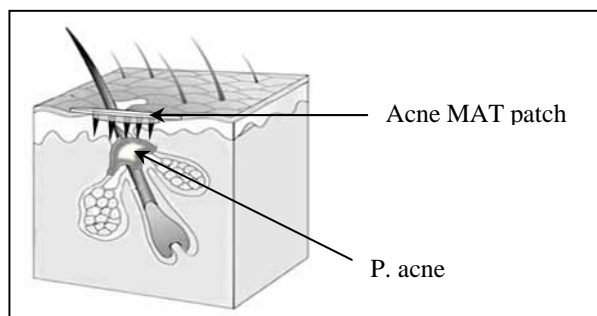
### ABSTRACT:

The versatile TheraJectMAT™, dissolvable micro-needle patch, contains API in an inert GRAS matrix. The system can deliver hundreds of micrograms of API rapidly through the stratum corneum into the epidermal tissue. This micro-needle patch technology can be applied effectively for cosmeceutical applications such as acne treatment.

### INTRODUCTION:

Acne is a common skin disorder affecting at least 85 percent of adolescents and young adults. Acne is a chronic inflammatory disorder of the pilosebaceous unit. Currently over the counter (OTC) products including topical cleansers, astringents and benzoyl peroxide (BP) are minimally effective due to poor drug delivery<sup>1</sup>. The dissolvable transdermal micro-needle patch containing API can overcome the stratum corneum barrier function<sup>2</sup> and deliver an effective API payload to the pilosebaceous more effectively and without pain (Fig.1).

Fig. 1: Schematic diagram of Acne MAT patch delivery to pilosebaceous unit under stratum corneum.

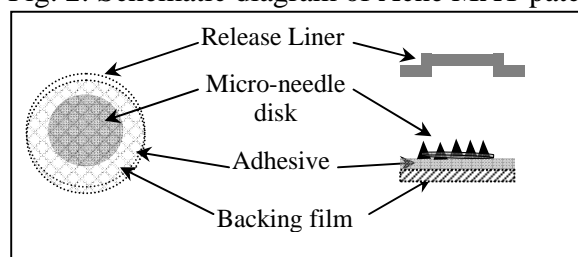


Acne gels can be applied prior or subsequently to the acne to continuously deliver additional API through the micro-pore to the target tissue.

### EXPERIMENTAL METHODS:

Ascorbic acid and BP were obtained from Sigma and sodium carboxymethylcellulose (CMC) from Hercules are dissolved in D.I. water at a predetermined ratio (1% BP). The resulting gel was cast into a mold by centrifugation and dried under ambient conditions. When dried, the micro-needle matrix was separated from the mold and cut into 7/16" diameter discs each having 25 micro-needles. The full length of each micro-needle is 1.2mm. The disk is integrated into a patch delivery system (Fig. 2).

Fig. 2: Schematic diagram of Acne MAT patch



Three different treatments were evaluated in a clinical pilot study. Treatment 1 is application of a BP micro-needle patch. Treatment 2 is an acne gel application followed by a placebo micro-needle patch. Treatment 3 is application of a BP micro-needle patch followed by an acne gel. Transepidermal water loss (TEWL) of the treated site is measured by the Tewameter TM21 (Courage and Khazaka, Germany) and the images are photographed. The acne gel is a commercial product containing 2.5% BP. This pilot clinical trial was designed and performed internally to demonstrate feasibility with a prototype micro-needle patch.

### RESULTS AND DISCUSSION:

The TEWL value from intact facial skin and opened acne site are 25 and 63 (g/m<sup>2</sup>/h) respectively (Table 1). The TEWL value of an untreated acne site, 30-40 (g/m<sup>2</sup>/h), is higher than an intact site due to partial compromise of stratum corneum but lower than that of a fully

opened acne site. The TEWL with acne treatments increase to 62-65(g/m<sup>2</sup>/h). This indicates patch application created micro-pores on the acne site. The micro-pores permit the delivery of additional BP to P. acne.

Table 1: TEWL values (g/m<sup>2</sup>/h) of different facial skin conditions and treatments

Skin conditions	TEWL measurement	
Intact facial skin	25.0 ± 1.77	
Ruptured acne site	63.1 ± 3.53	
<u>Patch application</u>	<u>Before</u>	<u>After</u>
Treatment 1	34.7 ± 2.23	65.2 ± 1.63
Treatment 2	41.0 ± 4.11	64.8 ± 4.64
Treatment 3	29.0 ± 3.40	42.5 ± 5.89

Fig.3 shows the images of drug micro-needle systems before and after insertion. Most of the micro-needles dissolved overnight and consequently the BP and vitamin C in the micro-needle composition are released into the skin lesion. In Fig. 4 (a) and (b) are images of the acne sites before and after overnight micro-needle patch application. Fig.5 (a), (b) are images of treatment 2, applying acne gel first and subsequent overnight vitamin C micro-needle patch. Fig.6 (a), (b) are images of treatment 3, the BP micro-needle patch followed by an acne gel application.

Fig.3: Image of micro-needles before and after insertion into facial skin.




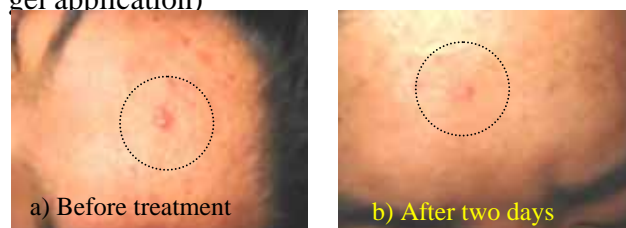
Fig.4: Image of facial skins of Treatment 1 (before and after BP micro-needles insertion)

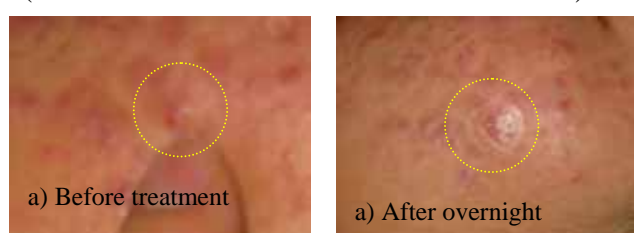

Fig.5: Image of facial skins of Treatment 2 (acne gel application to cheek followed by vitamin C micro-needles insertion)

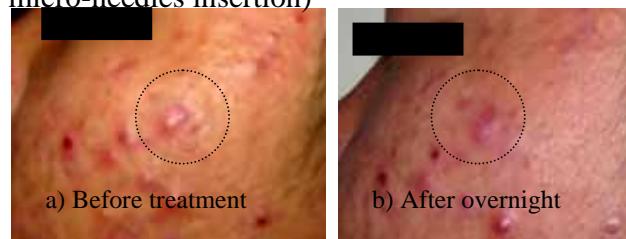

Fig.6: Image of facial skins of Treatment 3 (BP micro-needles insertion on forehead then acne gel application)



The acne severity decreased significantly and rapidly after micro-needle patch and gel treatment. The combination treatments (2 and 3) appear more effective than the micro-needle patch alone. The treated acne sites became soft and smooth after all treatments. The sensation associated with micro-needle injections was mild and neither local adverse effect on skin nor any discomfort was observed.

**CONCLUSION:** Preliminary clinical data presented here clearly show that micro-needle patches with acne gel application can treat P. acne rapidly and effectively. The API in the gel is delivered through the micro-pores created by micro-needle insertion. Further systemic clinical study with optimized API formulation is needed for product development.

#### REFERENCES:

1. A. Kasprowicz, L. Krowczynski, R. Jachowicz, and A. Bialecka, Erythromycin and penetrating agents containing ointment in acne vulgaris therapy, *Pol J Pharmacol Pharm.* 1988, 40(5): 465-9.
2. S.Y. Kwon, S. Oh and T.L Burkoth, Rapid Intradermal Drug Delivery by a Dissolvable Micro-Needle Patch. *Controlled Release Society 32<sup>nd</sup> Annual Meeting 2005, #306.*